

Title: Image fusion of the preoperative biopsy-proven 3D cancer model and the intraoperative 3D cryolesion: Assessment of therapeutic adequacy in lesion-targeted cryotherapy for prostate cancer.

Author: Masahiko Nakamoto\*†, Osamu Ukimura\*, Norio Fukuda†, Sunao Shoji\*, Andre L. C. Abreu\*, Scott Leslie\*, Yoshinobu Sato†, Inderbir S. Gill\*

\* USC Institute of Urology, Hillard and Roclyn Herzog Center for Prostate Cancer Focal Therapy, Keck School of Medicine, University of Southern California, Los Angeles, CA

† Department of Radiology, Graduate School of Medicine, Osaka University, Suita, Japan

Introduction: Real-time 2D TRUS and thermocouple sensors are used for monitoring the adequacy of cryoablation to treat the entire cancer by lethal freezing temperatures. However, understanding of the spatial distribution of the ice ball is difficult with only 2D TRUS, requiring significant radiological expertise. We developed a technique to reconstruct 3D models of the prostate and the biopsy-proven cancer by continuous scanning of the prostate with simultaneous biplanar TRUS [1]. This study aims to evaluate the feasibility of image fusion between the preoperative and intraoperative 3D TRUS images for assessment of therapeutic adequacy in lesion-targeted cryoablation.

Methods: Diagnostic prostate biopsy was performed using UroStation (KOELIS, La tronche, France) which allowed 3D TRUS based tracking and documentation of each biopsy trajectory. The prostate and biopsy-proven, image-visible cancer were manually segmented by an experienced urologist using Synapse VINCENT (FUJIFILM, Tokyo, Japan) to reconstruct pre-operative 3D models. The length and position of cancer on each biopsy was determined by pathological examination and these defined the red-color-coding of the biopsy trajectory. At the time of cryoablation biplanar TRUS scanning of the prostate was performed to reconstruct intraoperative 3D models of the cryolesion (ice ball) [1]. Since the anterior aspect of the ice ball is ambiguous due to acoustic shadowing, the anterior contours were determined by interpolation of visible posterior contours. The preoperative and intraoperative 3D models were registered by

rigid registration between the posterior and lateral surfaces.

Results: We applied the image fusion technique in two cases undergoing lesion-targeted cryoablation for prostate cancer. The registered 3D models confirmed that the preoperatively reconstructed cancer model was fully contained within the reconstructed ice ball, indicating that lethal freezing temperatures were attained (Fig. 1).

Conclusion: Our image fusion technique of the preoperative 3D cancer model and the intraoperative 3D cryolesion potentially enhances assessment of therapeutic adequacy for focal cryotherapy. (298 words)

[1] M. Nakamoto et al., "VS14-03 REALTIME TRACKING OF BIPLANE TRUS IMAGES BY IMAGE REGISTRATION ACCELERATED WITH GRAPHICS PROCESSING UNIT - PRELIMINARY PHANTOM STUDY -," *Journal of Endourology*, vol. 25, no. 1, p. A338, Nov. 2011.

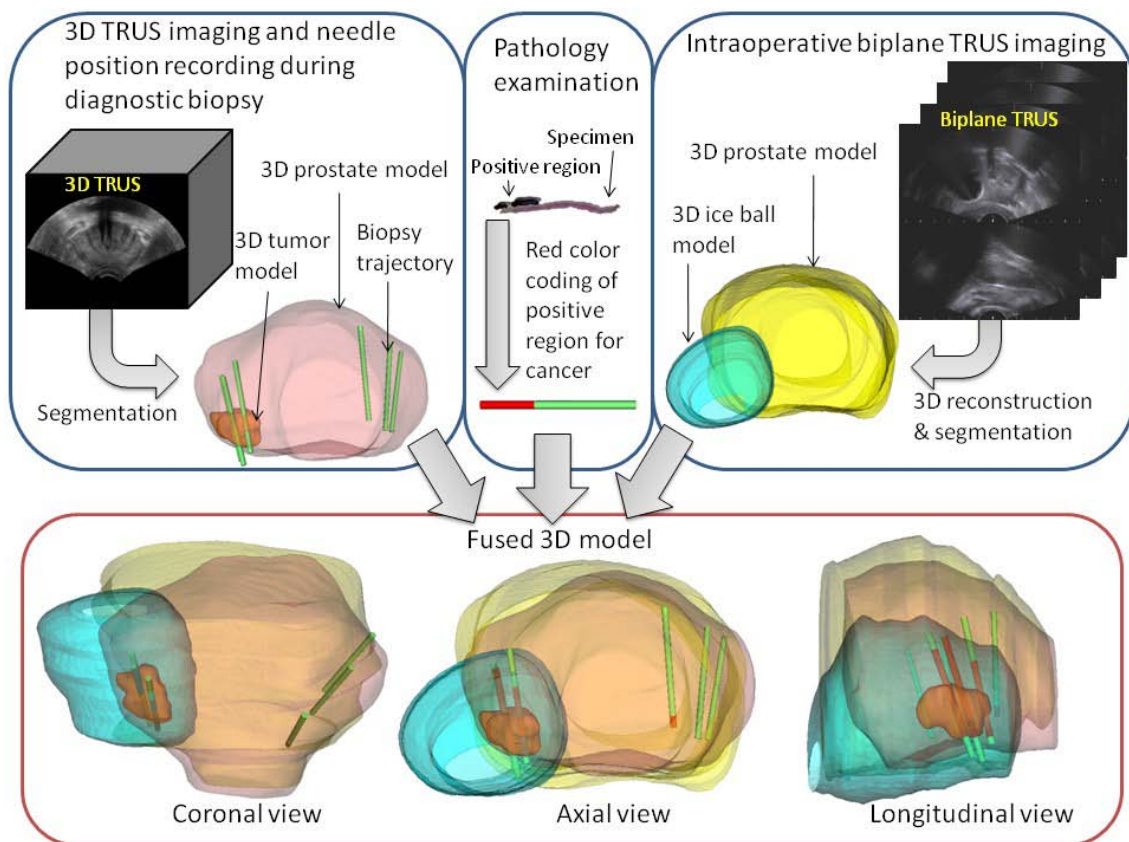


Fig.1: Diagram of image fusion process and resulting fused 3D model.